

OD OP:
46 dB

10/2/96

11:21 AM

LOG

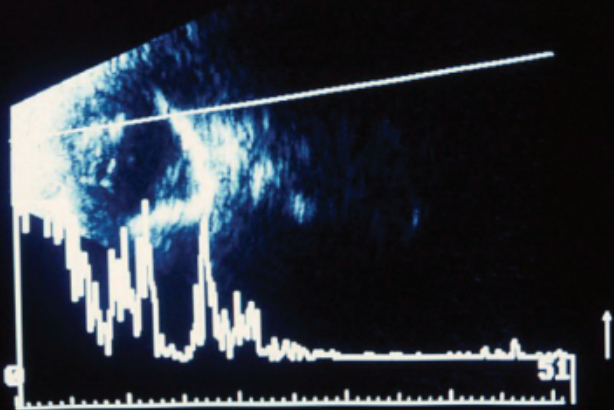


Figure 3 Ultrasonography showing the presence of dense retrolental echogenicities and retinal elevation